

# Routine Ultrasonography for Intensified Tuberculosis Case Finding in High Human Immunodeficiency Virus (HIV) and Tuberculosis (TB) Burdened Countries: A Proposed Frame Work

Geofery Luntsi<sup>1\*</sup>, Anthony Chukwuka Ugwu<sup>2</sup>, Muhammad Sani Ahmadu<sup>3</sup>, Christopher Chukwuemeka Ohagwu<sup>2</sup>, Mohammed Sidi<sup>4</sup>, Kalu Ochie<sup>5</sup>, Emmanuel Peter Mshelia<sup>1</sup>, Akwa Egom Erim<sup>6</sup>, Umar Abubakar<sup>7</sup>, Flavious Bobuin Nkubli<sup>1</sup>, Chigozie Ivor Nwobi<sup>1</sup>, Eberechukwu Ayogu<sup>8</sup>

<sup>1</sup>Department of Medical Radiography, Faculty of Allied Health Sciences, College of Medical Sciences, University of Maiduguri, Maiduguri, Nigeria, <sup>2</sup>Department of Radiography and Radiological Sciences, Faculty of Health Sciences, Nnamdi Azikiwe University, Awka, Nigeria, <sup>3</sup>Department of Radiology, University of Maiduguri Teaching Hospital, Maiduguri, Borno State, Nigeria, <sup>4</sup>Department of Medical Radiography, Faculty of Allied Health Sciences, College of Medical Sciences, Bayero University Kano, Kano, Nigeria, <sup>5</sup>Department of Radiography and Radiological Sciences, Faculty of Allied Health Sciences, Evangel University, Ebonyi State, Nigeria, <sup>6</sup>Department of Radiography and Radiological Sciences, Faculty of Health Sciences, University of Calabar, Calabar, Nigeria, <sup>7</sup>Department of Medical Radiography, Faculty of Allied Health Sciences, College of Medical Sciences, Usmanu Danfodiyo University, Sokoto, <sup>8</sup>Department of Radiology, Enugu State Teaching Hospital, Parkline Enugu, Enugu State, Nigeria

## Abstract

Sonography has proven to be valuable diagnostic imaging equipment in the work-up of patients infected with acquired immune deficiency syndrome (AIDS) and tuberculosis (TB) coinfection. An extensive literature search was conducted between 1994 and 2021 for original peer-reviewed articles in the English language on ultrasound application in the diagnosis of extrapulmonary TB (EPTB), ultrasound application in infectious diseases in resource-constrained settings, point-of-care ultrasound in resource-scarce settings among others, across various electronic databases including MEDLINE, PubMed, POPLINE, Scopus and Google Scholar, among others and some gray literature were also retrieved. Emerging themes were identified by their recurrence in literature. Ultrasound imaging is a rapid diagnostic tool and can accurately identify and characterize pathologic findings in patients infected with HIV/AIDS and TB co-infection, such as enlarged lymph nodes, pericarditis, and pleural effusion, among others for prompt patient management. Ultrasonography is cheaper and portable; interfacing software has become more users friendly and image quality significantly improved, making it possible for the provision of imaging services in an increasing number of clinical settings in resource-limited settings where access to diagnostic imaging is scarce. The use of focused assessment with sonography for HIV (FASH) for prompt diagnosis of EPTB in regions with a high incidence of HIV/AIDS and TB co-infection will aid in prompt diagnosis and treatment of patients with undifferentiated TB, thus impacting on morbidity and mortality. The training and deployment of sonographers in endemic regions with a high prevalence of HIV/AIDS and TB co-infection, to diagnose EPTB using FASH protocol is a viable option that is in line with the global drive for intensified case finding and treatment algorithm, with a view to meeting the sustainable development goals target of ending HIV and TB epidemics and achieving universal health coverage.

**Keywords:** Extra-pulmonary tuberculosis, focused assessment with sonography for HIV, point-of-care ultrasound, tuberculosis, ultrasonography

## INTRODUCTION

Tuberculosis (TB) is one of the top infectious killer diseases the world over. Developing countries account for more than 95% of TB deaths, with over a million children diagnosed with TB and about 170,000 deaths resulting from TB among

**Address for correspondence:** Dr. Geofery Luntsi, Department of Medical Radiography, Faculty of Allied Health Sciences, College of Medical Sciences, University of Maiduguri, Maiduguri, Nigeria. E-mail: [geostuff@unimaid.edu.ng](mailto:geostuff@unimaid.edu.ng)

Received: 12-03-2022 Revised: 28-04-2022 Accepted: 10-06-2022 Available Online: 07-10-2022

### Access this article online

#### Quick Response Code:



Website:  
[www.jmuonline.org](http://www.jmuonline.org)

DOI:  
10.4103/jmu.jmu\_25\_22

This is an open access journal, and articles are distributed under the terms of the Creative Commons Attribution-NonCommercial-ShareAlike 4.0 License, which allows others to remix, tweak, and build upon the work non-commercially, as long as appropriate credit is given and the new creations are licensed under the identical terms.

**For reprints contact:** [WKHLRPMedknow\\_reprints@wolterskluwer.com](mailto:WKHLRPMedknow_reprints@wolterskluwer.com)

**How to cite this article:** Luntsi G, Ugwu AC, Ahmadu MS, Ohagwu CC, Sidi M, Ochie K, *et al.* Routine ultrasonography for intensified tuberculosis case finding in high human immunodeficiency virus (HIV) and tuberculosis (TB) burdened countries: A proposed frame work. *J Med Ultrasound* 2022;30:245-50.

children, excluding children with HIV/acquired immune deficiency syndrome (AIDS).<sup>[1]</sup> Mycobacterium TB is the causative agent for TB, it is curable and preventable.<sup>[2]</sup> Hence, many people though not ill are infected with TB, although they may not transmit the disease yet. Infected persons have a lifetime risk of 5%–10% becoming ill from TB. People who are immunocompromised like persons infected with AIDS have an increased risk of up to 18 times more being infected with TB. Malnourished persons, diabetics, and tobacco smokers are at higher risk of falling ill.<sup>[2]</sup>

More than a million people died from TB infection in 2019 only, with over 200,000 persons living with HIV/AIDS. TB infected more than 10 million persons the world over, with almost a ratio of 2:1 among the male and female gender and about 1.2 million children. The highest-burdened countries that recorded over 87% of new cases of infection were countries such as India, Indonesia and China, the Philippines, Pakistan, Nigeria, Bangladesh, and South Africa accounting for up to two-thirds of the total cases of TB infection. The decline in TB infection globally is gradual but steady; the reported decline between 2015 and 2019 was 9% which is far from the end TB target of 20% reduction by 2020.<sup>[2]</sup>

## PULMONARY TUBERCULOSIS AND EXTRAPULMONARY TUBERCULOSIS

Pulmonary tuberculosis (PTB) is caused by the mycobacterium TB complex and is mainly transmitted by droplet spray. When an infected person coughs, sneezes, or speaks, and produces droplets that could be suspended in the air for several hours, which may get inhaled into the lungs.<sup>[2,3]</sup>

Extrapulmonary TB (EPTB) is blood-borne spread, or through direct invasion from the nearby organs.<sup>[3]</sup> The disease is subtle with a minimal manifestation of symptoms that exacerbates with time. Productive cough, hemoptysis, fatigue, emaciation, restlessness, fever, and drenching night sweats. Nonspecific early symptoms make the clinical diagnosis and differentials of EPTB challenging. Several risk factors like HIV/AIDS, and diabetes among others, make clinical suspicion higher in these groups of patients. Every organ in the body can be infected with TB making it an important disease entity. The increasing prevalence of the risk factors has also resulted in an increased case of EPTB.<sup>[1,3,4]</sup>

Approximately 15%–20% of all TB cases reported in the African region are EPTB cases.<sup>[4,5]</sup> Extrapulmonary TB could manifest as pericardial effusion, pleural effusion, and abdominal TB among others. In high-burdened countries, abdominal TB is the common site for active EPTB in people living with HIV/AIDS<sup>[1,6-9]</sup> along with site other sites such as the lungs, the pleural, peripheral, and intrathoracic lymph nodes.<sup>[9]</sup> The nonspecific nature of the presentation of EPTB makes it difficult for clinical specimens for bacteriological confirmation, thus making diagnosis difficult and delayed, and disease may go undetected.<sup>[10]</sup> Morbidity

and mortality from HIV/AIDS-EPTB co-infection are highly significant,<sup>[9-11]</sup> efforts in achieving early and prompt diagnosis in resource-scarce settings with high TB burden is very essential in achieving the sustainable development goals (SDG) 3.3 global target of ending the epidemics of AIDS, TB, malaria, and other neglected diseases of the tropics, combat hepatitis, water-borne diseases, and other communicable diseases by 2030.<sup>[3]</sup>

## IMAGING INVESTIGATION OF EXTRA-PULMONARY TUBERCULOSIS

Radiology plays a vital role in the correct screening, confirmation, and documentation of the course of diseases. There is a considerable improvement in availability and access to imaging services globally; however, this is not equal across the globe.<sup>[12]</sup> Radiologic tools such as computed tomography and magnetic resonance imaging techniques help in better characterization of HIV/AIDS-related EPTB, especially in the abdomen; however, they are capital intensive, and not readily available in a typically limited resource environment with high incidence and burden of HIV/AIDS infections.<sup>[13]</sup> Despite the technological advances in the field of medical imaging, it is worthy of note that radiography (plain film) and sonography are the imaging workhorse in limited-resource settings as they both serve diagnostic and interventional roles, and also assist in directing appropriate therapy.<sup>[3]</sup>

Radiography is a cornerstone diagnostic imaging tool for the diagnosis and workup of pulmonary diseases; it is, however, limited in scope, particularly in the evaluation of intra-abdominal infections. Although plain film radiographs are able to pick up numerous signs secondary to disease conditions, including bowel obstruction, ileus, pneumoperitoneum (air in the bowel wall), among others, assessing inflammatory conditions is, however, difficult.<sup>[3]</sup> The diagnosis of EPTB is quite challenging because of the difficulty experienced in obtaining materials, poor sensitivity of microscopy, and limited availability of culture techniques, as a result, diagnosis relies heavily only on clinical case definitions.<sup>[14-16]</sup> Ultrasound imaging plays an all-important role in all groups of patients including children and adults alike. Effective clinical decision-making depends on the appropriate screening and triaging and diagnosis of patients.<sup>[12]</sup> Ultrasonography plays an important role within the evidence-based clinical decision support algorithms for disease management.<sup>[12,17]</sup> The literature is replicated the vital role played by ultrasound in the screening, and diagnosis documentation of EPTB in HIV/AIDS patients co-infected with TB, especially in TB endemic regions.<sup>[3,5,10,17,18]</sup> Among several reasons for ultrasonography usage in the workup of patients with TB to exclude EPTB among patients with HIV/AIDS are; its nonusage of ionizing radiation makes it suitable for all age groups including children<sup>[19]</sup> and can be adopted as a bedside routine treatment monitoring for patients in TB endemic regions where access to imaging services are scarce.<sup>[20]</sup>

**Table 1: Emerging themes from Systematic Literature Synthesis**

Emerging Themes	Authors
Pulmonary Tuberculosis (PTB) and Extra-Pulmonary Tuberculosis (EPTB)	Mollura <i>et al.</i> , 2019 <sup>[3]</sup> , Iliyasu and Babashani, 2009 <sup>[6]</sup> , Spalgais <i>et al.</i> , 2013 <sup>[7]</sup> , Borkar <i>et al.</i> , 2016 <sup>[8]</sup> , Spalgais <i>et al.</i> , 2017 <sup>[9]</sup> .
Imaging Investigation of Extra-Pulmonary Tuberculosis.	Mollura <i>et al.</i> , 2019 <sup>[3]</sup> , WHO, 2016 <sup>[12]</sup> , Trivedi <i>et al.</i> , 2015 <sup>[13]</sup> , Goblirsch <i>et al.</i> , 2014 <sup>[16]</sup> , Weber <i>et al.</i> , 2018 <sup>[18]</sup> , Heller <i>et al.</i> , 2013 <sup>[21]</sup> .
Focused Assessment with Sonography for HIV-Associated Tuberculosis (FASH)	Weber <i>et al.</i> , 2018 <sup>[18]</sup> , Mbanjumucyo and Henwood, 2016 <sup>[20]</sup> , Heller <i>et al.</i> , 2014 <sup>[22]</sup> , Sinkala <i>et al.</i> , 2009 <sup>[24]</sup> , Mateer <i>et al.</i> , 1994 <sup>[25]</sup> , CDC, 2016 <sup>[29]</sup> .
Common Manifestation of Extra-Pulmonary Tuberculosis (EPTB)	Mbanjumucyo and Henwood, 2016 <sup>[20]</sup> , Von-Reyn <i>et al.</i> , 2011 <sup>[35]</sup> , WHO, 2006 <sup>[36]</sup> , Brindle <i>et al.</i> , 2013 <sup>[37]</sup> , Giordani <i>et al.</i> , 2012 <sup>[38]</sup> .
Point of Care Ultrasound Training in Resource Constrained Settings	Heller <i>et al.</i> , 2012 <sup>[5]</sup> , Mbanjumucyo and Henwood, 2016 <sup>[20]</sup> , Van-Hoving <i>et al.</i> , 2013 <sup>[33]</sup> , Rozycki <i>et al.</i> , 1999 <sup>[40]</sup> , Heller <i>et al.</i> , 2010 <sup>[42]</sup> .

In most limited resource settings, a common challenge has always been the lack of trained and qualified sonographers and sonologist who can provide the needed imaging service demands of the teeming populace. Recently, point-of-care ultrasound (POCUS) has been a huge success following its introduction across a variety of settings. Dedicated protocols and techniques for the specific patient populations are needed to answer specific clinical questions. Specific protocols and techniques have been successfully developed and deployed in emergency medicine, like the focused assessment with sonography for trauma,<sup>[17,20]</sup> for the assessment of trauma victims. Similarly, the focused assessment with sonography for HIV (FASH)-TB co-infection protocol has also been developed.<sup>[10,20]</sup> The FASH/AIDS-associated TB has been successfully developed and is being used to diagnose signs of EPTB. This technique can be learned by healthcare personnel who are novices to ultrasound.<sup>[10]</sup> The technique consists of a rapid sonographic evaluation of the abdomen, pleural space, and the heart to roll out pleural and pericardial effusion, abdominal lymph enlargement, hypoechogenic lesions in the spleen and liver, ascites bowel wall thickening, among many others.<sup>[10]</sup> However, the majority of these cases go undetected due to the poor sensitivity of microbiological test.<sup>[21-23]</sup> Ultrasound potentials are limitless in the diagnosis and workup of patients with EPTB, especially in areas with high prevalence. Ultrasound is able to rapidly pick up the spectrum of findings that are classical or highly suggestive of EPTB.<sup>[24]</sup> Due to the shortage of sonographers and sonologist in constrained resource settings, modeled courses were developed to train physicians and healthcare providers on the focused application of ultrasound to achieve wider coverage. The public health implication is far-reaching in scarce resources with improved and rapid detection of EPTB in our teeming population, especially at the rural primary healthcare centers where most patients tend to seek healthcare services at first instance, to deliver immediate preventive, curative as well as palliative care.<sup>[3,10,17,24,25]</sup>

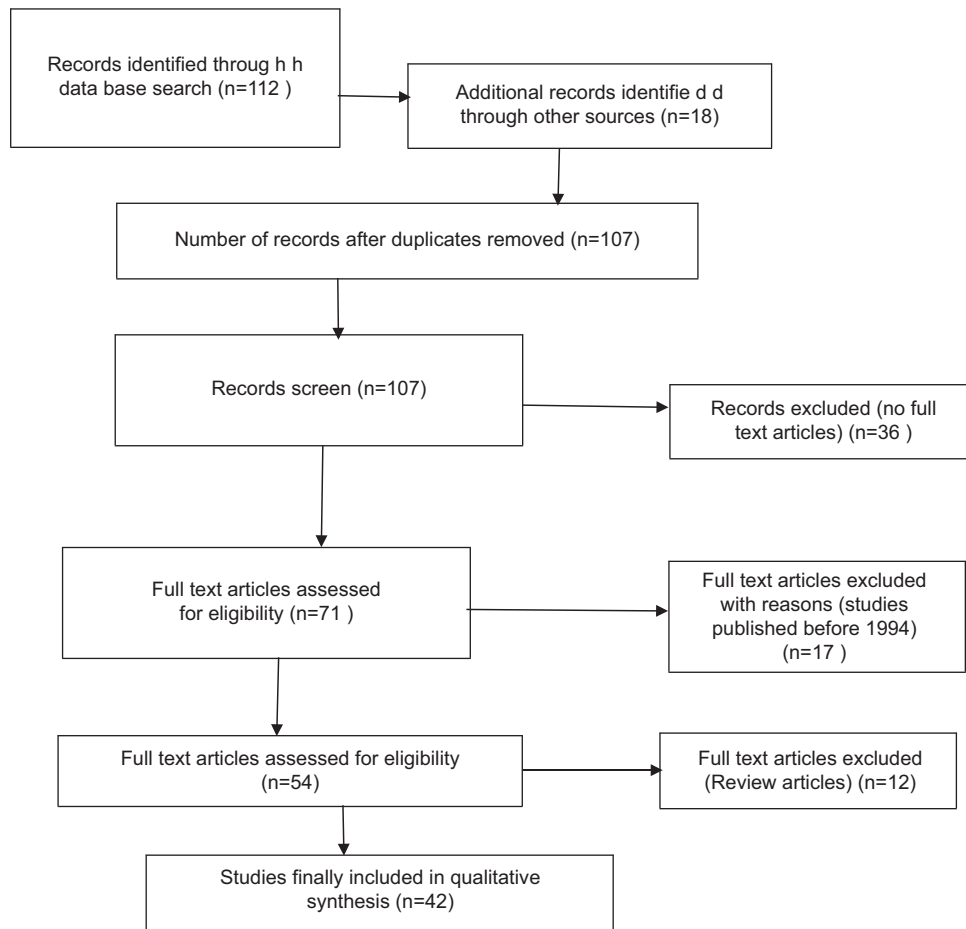
## MATERIALS AND METHODS

An extensive literature search was conducted between 1994 and 2021 for original peer-reviewed articles in the

English language on ultrasound application in the diagnosis of EPTB, ultrasound application in infectious diseases in resource-constrained settings, POCUS in resource-scarce settings among others, across various electronic databases including MEDLINE, PubMed, POPLINE, Scopus, and Google Scholar, among others and some grey literature was retrieved from some government agencies, WHO, and nongovernmental organizations. The search was extended by scrutinizing the reference list of the selected articles and only articles for which the full text was available were considered. This was done to ensure that many relevant studies were extracted on the subject. Systematic synthesis of the literature is presented in a flow chart in Figure 1 and emerging themes were identified by their recurrence in literature. Major themes are summarized in Table 1 and described in the results/discussion.

## ULTRASOUND FOR FOCUSED ASSESSMENT OF EXTRAPULMONARY TUBERCULOSIS

Globally, TB has been a major public health concern. The incidence of EPTB is high, up to 15% of the total new TB cases, with a higher preponderance in females than males, especially of African or Asian descent.<sup>[26-29]</sup> The diagnosis of EPTB is low due to a lack of point-of-care diagnostic tests.<sup>[20]</sup> Several organs are affected by EPTB making diagnosis challenging and requiring cross-sectional imaging. Patients (both adults and children) living with HIV/AIDS have an increased risk of contracting EPTB.<sup>[20,27]</sup> The double burden of HIV and TB in underdeveloped nations especially in sub-Saharan Africa makes the screening, diagnosis and prompt treatment of the incident cases a priority to reduce the cases and meet the SDG targets by 2030.<sup>[3]</sup> The use of POCUS the “FASH associated TB protocol” is coming in handy to support timely diagnosis and workup of these groups of patients.<sup>[24]</sup> There is however need to explore the application of FASH protocol outside HIV/TB endemic areas or among HIV-negative populations. In inpatient populations with low TB prevalence, ultrasound findings could be a result of other diseases other than TB, therefore, transferring FASH protocol from one epidemiological setting to another should be done with care.<sup>[18]</sup>



**Figure 1:** Systematic flowchart of the articles used in the study

There is an increased usage of imaging services like ultrasound in developing countries to support clinical decision-making and procedural guidance.<sup>[30]</sup> The FASH procedure however does not replace a comprehensive ultrasound examination, while POCUS techniques like FASH try to answer a specific clinical question, i.e., relevant to immediate patient case management.<sup>[18]</sup> Diagnostic ultrasound is performed by a highly trained healthcare professional with good knowledge of ultrasound equipment Knobology, who systematically assesses the sonographic images, records, and interprets the examination to provide a well-documented and recorded report of the finding and draw up a conclusion from the scan for diagnosis and management of patient conditions.<sup>[3,30]</sup> Formal training programs have been developed to train healthcare personnel in ultrasound skills.<sup>[25]</sup>

With the growing application of POCUS in infectious disease, criteria such as the prevalence of the disease among the patient population, the potential of the diagnosis to significantly change patient condition, and the simplicity of the protocol for reproducibility and for novice to learn with ease.<sup>[31,32]</sup> There is a slight difference in the application of POCUS in high-income countries and in resource-limited settings because it is deployed as a reduced time diagnosis to answer specific clinical questions to improve patient management in

high countries, while in limited-resource settings, POCUS may perhaps be the only available diagnostic imaging modality, thus making the issue of training and retraining an important issue.<sup>[20,32,33]</sup>

## COMMON MANIFESTATION OF EXTRAPULMONARY TUBERCULOSIS

EPTB is commonly seen in immune-suppressed patients, diagnosing EPTB is quite challenging compared to PTB. The major cause of death among HIV/AIDS patients is disseminated TB.<sup>[20,32,34]</sup> Commonly presenting clinical symptoms include but are not limited to fever, loss of weight, drenching sweats in the night, cough, and shortness of breath. Specific symptoms are less evident among individuals co-infected with HIV/AIDS.<sup>[20,32,35]</sup> Sonographic features that are suggestive of EPTB, especially in endemic populations are pericardial effusion.<sup>[37]</sup> Lymph node enlargement and micro-splenic abscesses within the abdomen are characteristic findings in HIV-TB co-infected patients.<sup>[38]</sup> Sonographically, they are seen as hypoechoic round structures larger than 1.5–2 cm. The common sites are the liver hilum, celiac and para-aortic area, caecal mesentery, and the splenic hilum.<sup>[20,32]</sup> Enlarged spleen with micro-abscesses in the spleen measuring



0.5–1 cm, the presence of ascites within the abdomen, are all features strongly suggestive of TB of the abdomen.<sup>[32]</sup>

## POINT-OF-CARE ULTRASOUND TRAINING IN RESOURCE-CONSTRAINED SETTINGS

Successful curriculum development, training, and deployment of healthcare personnel to carry out POCUS to identify features EPTB has been tried out through short courses in South Africa,<sup>[10]</sup> and also well demonstrated in emergency medicine.<sup>[22]</sup> Pleural effusion,<sup>[39]</sup> pericardial effusion,<sup>[40]</sup> and ascetic fluid are well demonstrated with POCUS with high sensitivity and specificity. The POCUS protocol for EPTB (FASH) has reported huge success rates in the detection of micro-splenic abscesses.<sup>[41]</sup> Over 25% of the patient population with negative chest X-ray findings had positive FASH findings, indicating that a huge number of the patient population whose EPTB diagnosis would have been missed if chest X-ray was the only imaging diagnostic test available.<sup>[20,32]</sup> The positive impact of FASH has also been reported among the pediatric patient population.<sup>[41]</sup> In evaluating patient response to treatment, FASH positive findings with EPTB after a 3 months' period of treatment present a challenge of mycobacterial resistance, poor compliance to the treatment regime, or immune reconstitution inflammatory syndrome.<sup>[29,41]</sup> It is imperative to note that ultrasonography alone cannot give a definitive diagnosis, however, in high prevalence settings, prompt TB treatment can be instituted following positive sonographic findings with good clinical suspicion.<sup>[10,20,42]</sup>

A major concern in diagnosing EPTB is the nonspecific symptomatic presentation resulting in most EPTB going unnoticed. As such abdominal ultrasound should be an adjunct imaging test to plain chest radiography imaging alongside other diagnostic tests among patients with suspected EPTB for the intensified case findings. It is, however, important to note that ultrasound is highly an operator-dependent imaging modality with high false-negative and false-positive rates, and a long learning curve that has impeded its wide usage. Routine follow-up ultrasound scans have been recommended as a way of monitoring the patient's response to treatment. We also did not conduct any statistical analysis in this review study.

## CONCLUSION

FASH has proved to come in handy in characterizing the common pathologic findings in patients living with HIV/AIDS and TB co-infection. It supports prompt decision-making in patients with suspicion of HIV/AIDS and TB co-infection to rule out EPTB in patient populations with high HIV/AIDS and TB incidence, where access to radiological imaging and microbiological investigations are limited, avoiding unnecessary delays to diagnosis and treatment, and thus impacting morbidity and mortality. Ultrasonography is a rapid diagnostic imaging tool that is readily available and affordable with technological advances making it portable and

user-friendly. The training and deployment of sonographers in endemic regions with a high prevalence of HIV and TB co-infection, to diagnose EPTB using FASH protocol is a viable option that is in line with the global drive for intensified case finding and treatment algorithm, with a view to meeting the SDG target of ending HIV and TB epidemics and achieving universal health coverage.

## Financial support and sponsorship

Nil.

## Conflicts of interest

There are no conflicts of interest.

## REFERENCES

1. World Health Organization Regional Office for Africa on Tuberculosis. Available from: <https://www.afro.who.int/news/tuberculosis>. [Last accessed on 2022 May 28].
2. World Health Organization. Media Center. Tuberculosis; 2020. Available from: <http://www.who.int/mediacentre/factsheets/fs104/en/>. [Last accessed on 2021 Mar 28].
3. Mollura DJ, Culp MP, Lungren MP. Radiology in Global Health Strategies, Implementation, and Applications. 2<sup>nd</sup> ed. Switzerland AG: Springer Nature; 2019.
4. World Health Organization. Global Tuberculosis Control: Epidemiology, Strategy, Financing. Geneva: World Health Organization; 2009. [https://apps.who.int/iris/bitstream/handle/10665/44241/9789241598866\\_eng.pdf](https://apps.who.int/iris/bitstream/handle/10665/44241/9789241598866_eng.pdf). [Last accessed on 2021 Mar 28].
5. Heller T, Wallrauch C, Goblirsch S, Brunetti E. Focused assessment with sonography for HIV-associated tuberculosis (FASH): A short protocol and a pictorial review. *Crit Ultrasound J* 2012;4:21.
6. Iliyasu Z, Babashani M. Prevalence and predictors of tuberculosis coinfection among HIV-seropositive patients attending the Aminu Kano Teaching Hospital, northern Nigeria. *J Epidemiol* 2009;19:81-7.
7. Spalgais S, Jaiswal A, Puri M, Sarin R, Agarwal U. Clinical profile and diagnosis of extrapulmonary tb in HIV infected patients: Routine abdominal ultrasonography increases detection of abdominal tuberculosis. *Indian J Tuberc* 2013;60:147-53.
8. Borkar MS, Joshi AS, Kashid AA, Gawale CG, Kakade RD, Chimote HN. Clinical profile of 128 HIV positive cases with abdominal tuberculosis. *Int J Sci Rep* 2016;2:18-24.
9. Spalgais S, Agarwal U, Sarin R, Chauhan D, Yadav A, Jaiswal A. Role of routine abdominal ultrasonography in intensified tuberculosis case finding algorithms at HIV clinics in high TB burden settings. *BMC Infect Dis* 2017;17:351.
10. Heller T, Wallrauch C, Lessells RJ, Goblirsch S, Brunetti E. Short course for focused assessment with sonography for human immunodeficiency virus/tuberculosis: Preliminary results in a rural setting in South Africa with high prevalence of human immunodeficiency virus and tuberculosis. *Am J Trop Med Hyg* 2010;82:512-5.
11. Fee MJ, Oo MM, Gabayan AE, Radin DR, Barnes PF. Abdominal tuberculosis in patients infected with the human immunodeficiency virus. *Clin Infect Dis* 1995;20:938-44.
12. World Health Organization. Diagnostic Imaging – Imaging Modalities. Geneva: World Health Organization; 2016 Available from: [http://www.who.int/diagnostic\\_imaging/en/](http://www.who.int/diagnostic_imaging/en/). [Last accessed 2021 Mar 24].
13. Trivedi A, Trivedi A, Panchal M, Jethva M, Yadav M. Abdominal ultrasonography findings in HIV infected patients. *Sch J App Med Sci* 2015;3:504-7.
14. Jones BE, Young SM, Antoniskis D, Davidson PT, Kramer F, Barnes PF. Relationship of the manifestations of tuberculosis to CD4 cell counts in patients with human immunodeficiency virus infection. *Am Rev Respir Dis* 1993;148:1292-7.
15. World Health Organization. Improving the Diagnosis and Treatment of Smear-Negative Pulmonary and Extra-Pulmonary Tuberculosis among Adults and Adolescents. Recommendations for HIV-Prevalent and

- Resource-Constrained Settings. Geneva: World Health Organization; 2007. Available from: [https://www.who.int/tb/publications/2006/tbhiv\\_recommendations.pdf](https://www.who.int/tb/publications/2006/tbhiv_recommendations.pdf). [Last accessed on 2021 Aug 29].
16. Goblirsch S, Bahlas S, Ahmed M, Brunetti E, Wallrauch C, Heller T. Ultrasound findings in cases of extrapulmonary TB in patients with HIV infection in Jeddah, Saudi Arabia. *Asian Pac J Trop Dis* 2014;4:14-7.
17. World Health Organization. The Hospital in Rural and Urban Districts: Report of a WHO Study Group on the Functions of Hospitals at the First Referral Level. Geneva: World Health Organization; 1992. Available from: [http://apps.who.int/iris/bitstream/10665/37704/1/WHO\\_TRS\\_819.pdf](http://apps.who.int/iris/bitstream/10665/37704/1/WHO_TRS_819.pdf). [Last accessed 2021 Mar 25].
18. Weber SF, Saravu K, Heller T, Kadavigere R, Vishwanath S, Gehring S, *et al.* Point-of-care ultrasound for extrapulmonary tuberculosis in India: A prospective cohort study in HIV-positive and HIV-negative presumptive tuberculosis patients. *Am J Trop Med Hyg* 2018;98:266-73.
19. Andronikou S, Wieselthaler N. Modern imaging of tuberculosis in children: Thoracic, central venous system and abdominal tuberculosis. *Pediatr Radiol* 2004;34:861-75.
20. Mbanjumucyo G, Henwood CP. Focused assessment with sonography for HIV-associated tuberculosis (FASH) case series from a Rwandan district hospital. *Afr J Emerg Med* 2016;6:198-201.
21. Heller T, Goblirsch S, Bahlas S, Ahmed M, Giordani MT, Wallrauch C, *et al.* Diagnostic value of FASH ultrasound and chest X-ray in HIV-co-infected patients with abdominal tuberculosis. *Int J Tuberc Lung Dis* 2013;17:342-4.
22. Heller T, Wallrauch C, Brunetti E, Giordani MT. Changes of FASH ultrasound findings in TB-HIV patients during anti-tuberculosis treatment. *Int J Tuberc Lung Dis* 2014;18:837-9.
23. Skoura E, Zumla A, Bomanji J. Imaging in tuberculosis. *Int J Infect Dis* 2015;32:87-93.
24. Sinkala E, Gray S, Zulu I, Mudenda V, Zimba L, Vermund SH, *et al.* Clinical and ultrasonographic features of abdominal tuberculosis in HIV positive adults in Zambia. *BMC Infect Dis* 2009;9:44.
25. Mateer J, Plummer D, Heller M, Olson D, Jehle D, Overton D, *et al.* Model curriculum for physician training in emergency ultrasonography. *Ann Emerg Med* 1994;23:95-102.
26. Gonzalez OY, Adams G, Teeter LD, Bui TT, Musser JM, Graviss EA. Extra-pulmonary manifestations in a large metropolitan area with a low incidence of tuberculosis. *Int J Tuberc Lung Dis* 2003;7:1178-85.
27. Jorstad MD, Aßmus J, Marijani M, Sviland L, Mustafa T. Diagnostic delay in extrapulmonary tuberculosis and impact on patient morbidity: A study from Zanzibar. *PLoS One* 2018;13:e0203593.
28. WHO. Global Tuberculosis Report 2016. Geneva, Switzerland: World Health Organization; 2016. <https://apps.who.int/iris/handle/10665/250441>. [Last accessed on 2021 Mar 28].
29. Centers for Disease Control (CDC) and Prevention C, 2016. TB in Children. Available from: <http://www.cdc.gov/tb/topic/populations/tbinchildren/>. [Last accessed on 2021 Aug 29].
30. Pinto A, Pinto F, Faggian A, Rubini G, Caranci F, Macarini L, *et al.* Sources of error in emergency ultrasonography. *Crit Ultrasound J* 2013;5 Suppl 1:S1.
31. Moore CL, Copel JA. Point-of-care ultrasonography. *N Engl J Med* 2011;364:749-57.
32. International Federation for Emergency Medicine (IFEM). Point-of-Care Ultrasound Curriculum Guidelines 2014. West Melbourne VIC 3003. <http://www.ifem.cc/Resources/PoliciesandGuidelines.aspx>.
33. van Hoving DJ, Lamprecht HH, Stander M, Vallabh K, Fredericks D, Louw P, *et al.* Adequacy of the emergency point-of-care ultrasound core curriculum for the local burden of disease in South Africa. *Emerg Med J* 2013;30:312-5.
34. Shah S, Noble VE, Umulisa I, Dushimiyimana JM, Bukhman G, Mukherjee J, *et al.* Development of an ultrasound training curriculum in a limited resource international setting: Successes and challenges of ultrasound training in rural Rwanda. *Int J Emerg Med* 2008;1:193-6.
35. von Reyn CF, Kimambo S, Mtei L, Arbeit RD, Maro I, Bakari M, *et al.* Disseminated tuberculosis in human immunodeficiency virus infection: Ineffective immunity, polyclonal disease and high mortality. *Int J Tuberc Lung Dis* 2011;15:1087-92.
36. WHO. Improving the Diagnosis and Treatment of Smear – Negative Pulmonary and Extrapulmonary Tuberculosis among Adults and Adolescents: Recommendations for HIV-Prevalent and Resource-Constrained Settings; 2006. Available from: [http://www.who.int/tb/publications/2006/tbhiv\\_recommendations.pdf](http://www.who.int/tb/publications/2006/tbhiv_recommendations.pdf). [Last accessed on 2021 Jul 23].
37. Brindle HE, Allain TJ, Kampondeni S, Kayange N, Faragher B, Bates I, *et al.* Utilization of ultrasound in medical inpatients in Malawi. *Trans R Soc Trop Med Hyg* 2013;107:405-10.
38. Giordani MT, Brunetti E, Binazzi R, Benedetti P, Stecca C, Goblirsch S, *et al.* Extrapulmonary mycobacterial infections in a cohort of HIV-positive patients: Ultrasound experience from Vicenza, Italy. *Infection* 2013;41:409-14.
39. Ma OJ, Mateer JR. Trauma ultrasound examination versus chest radiography in the detection of hemothorax. *Ann Emerg Med* 1997;29:312-5.
40. Rozycki GS, Feliciano DV, Ochsner MG, Knudson MM, Hoyt DB, Davis F, *et al.* The role of ultrasound in patients with possible penetrating cardiac wounds: A prospective multicenter study. *J Trauma* 1999;46:543-51.
41. Bèlard S, Heller T, Grobusch MP, Zar HJ. Point-of-care ultrasound: A simple protocol to improve diagnosis of childhood tuberculosis. *Pediatr Radiol* 2014;44:679-80.
42. Heller T, Lessells RJ, Wallrauch C, Brunetti E. TB pericarditis with cardiac tamponade: Management in the resource-limited setting. *AJTMH* 2010;83:1311-4.